

Massive spontaneous iliopsoas bursa mistaken as a deep vein thrombosis

RP. Jeavons¹, DJ. Ryan², D. Downen³, S. O'Brien³

Abstract

Introduction: Iliopsoas bursitis is a well-documented problem in those with an active disease process of the hip, and may present with a variety of symptoms. .

Case Report: A 68-year old gentleman presented to our unit with symptoms of proximal neurovascular compression, initially mistaken for a deep vein thrombosis. Further investigation revealed the cause to be a massive iliopsoas bursa requiring surgical excision. In our case, massive iliopsoas bursitis occurred in a patient with no prior symptomatic hip joint pathology. A review of symptoms and appropriate use of imaging techniques aided in correctly diagnosing the patient and with pre-operative planning.

Conclusion: A spontaneous, massive iliopsoas bursa in a fit and well patient is very rare. Prompt accurate diagnosis and management is required to ensure rapid resolution and prevent further complications.

Keywords: Iliopsoas bursitis, deep vein thrombosis, surgical excision.

Introduction

Iliopsoas bursitis is a well-documented condition. Presentation ranges from groin pain to proximal neurovascular compression. The majority of reported cases occurred in patients with an active disease process of the hip joint, following trauma or surgery [2,3,4]. Massive iliopsoas bursa (IB) can cause compression of local neurovascular structures, and requires rapid diagnosis and treatment.

Here we present, to our knowledge, the first case of a massive spontaneous iliopsoas bursa causing neurovascular compromise in a fit and well patient, mistakenly diagnosed and treated as a deep vein thrombosis (DVT).

Case Report

A 68 year old man, with a past medical history of hypertension and gout, presented to the Acute Medical Unit, with a one week history of right groin and leg pain; associated groin mass, erythema and pitting oedema involving the right thigh and lower limb and paraesthesia of

the medial thigh and knee. He had no symptoms of infection or neoplastic process. Blood tests revealed normal serum electrolytes, white cell count of 8.43 (4-10 x 10⁹/l), C-reactive protein of 10 mg/l (0-10 mg/l), erythrocyte sedimentation rate of 5 mm/hr and D-dimer level of 271 ng/ml (0-243 ng/ml).


A provisional diagnosis of DVT was made on the medical unit on the basis of the symptoms of lower leg pain, swelling, erythema and a mildly raised D dimer. The combination of calf swelling > 3cm, pitting oedema and entire leg swelling on the affected side gave a Wells' score of 3, placing the patient in the high risk group for DVT, and anticoagulant therapy was begun. An ultrasound scan of his leg twenty-four hours later, however, revealed only a small non-occlusive thrombus in a proximal peroneal calf vein, fully compressible right common femoral, superficial femoral, posterior tibial and popliteal veins, and normal flow on colour Doppler. A large fluid collection was noted around the right hip joint, leading to anticoagulation treatment being stopped in case of bleeding.

Access this article online

Website:
www.surgicalcasesjournal.com

DOI:

Author's Photo Gallery



Dr. DJ. Ryan

¹Department of Trauma and Orthopaedics, North Tees University Hospital, Stockton-on-Tees, UK

²Department of Trauma and Orthopaedics, Gloucestershire Royal Hospital, Gloucester. UK

³Department of Trauma and Orthopaedics, Sunderland Royal Hospital, Sunderland. UK

Address of Correspondence

Mr Daniel Ryan
Flat 6, Hendre, Overton Park Road, Cheltenham, Gloucestershire, GL50 3BW. UK
Email: Danny.ryan@cantab.net

Copyright © 2015 by International Journal of Surgical Cases

International Journal of Surgical Cases | eISSN 2321-3817 | Available on www.surgicalcasesjournal.com/ |

This is an Open Access article distributed under the terms of the Creative Commons Attribution Non-Commercial License (<http://creativecommons.org/licenses/by-nc/3.0>) which permits unrestricted non-commercial use, distribution, and reproduction in any medium, provided the original work is properly cited.

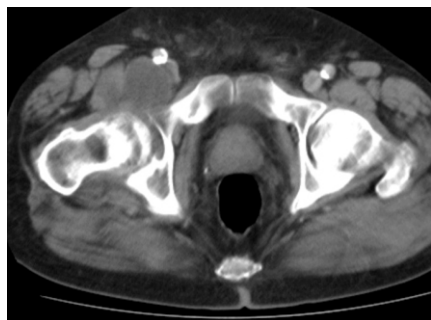

Figure 1. Axial CT Scan showing enlarged IB anterior to right hip.

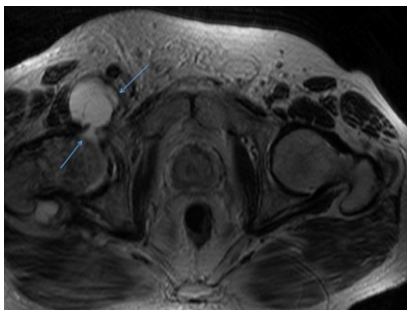


Figure 2a. T1 weighted MR image of IB anterior to the hip joint. It shows a clear communication.

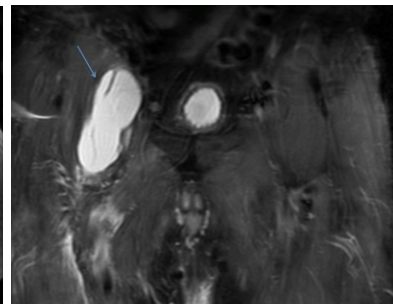


Figure 2b. Coronal MR image depicting the enlarged IB, aiding with planning of surgical approach.

The patient experienced no improvement in symptoms with conservative management, and owing to the persistence of swelling and pain, a local malignancy was suspected. A Computerised Tomography (CT) scan of his pelvis, performed 3 months after initial presentation, confirmed a 7x6.3 cm soft tissue mass anterior to the right hip (figure 1). Urgent referral to our Orthopaedic department for possible soft tissue neoplasia was made. On presentation at this time the patient complained of groin pain, paraesthesia in his thigh and significant lower limb swelling.

Extensive pitting oedema of the right lower leg was present. A large, firm, tender mass in the right groin was palpated, with the femoral artery palpable anteriorly. Distal pulses were present. There was reduced sensation over the medial aspect of the right thigh and below the knee: all other neurological testing was normal.

Magnetic Resonance (MR) scanning (figures 2a & b) demonstrated the mass to be anterior to, and communicating with the hip joint, lying posterior to the femoral vessels and causing compression. Altered bone marrow signal was noted in the femoral head and neck. A diagnosis of a massive iliopsoas bursa was made, based on the high signal appearance on T2 of a fluid-filled structure communicating with the joint (figure 2b).

Expedient exploration of the right groin and excision of the mass via an anterior approach was undertaken. The bursa protruded between the femoral artery and nerve, causing compression at this point. An opening created between the femoral neurovascular structures was used to remove the mass. The bursa was found to communicate directly with the hip joint, and the capsule was incised to allow complete excision. Following removal, the joint capsule was repaired with a simple suture using a heavy, absorbable, polyfilament material (Vicryl). Post operatively, the patient was mobilised as pain allowed. At 3 week follow up, his scar had healed, all lower limb swelling and groin pain had subsided, paraesthesia of the medial thigh and knee persisted, but resolved by 6 weeks, at which point he was discharged. Histology revealed inflammatory cells and hyalinised collagen fibres, consistent with the radiological diagnosis of an enlarged bursa.

Discussion

The IB is the largest periarticular synovial lined bursa of the hip region, located between the musculotendinous portion of the iliopsoas and the anterior aspect of the hip joint, in a collapsed state. It communicates with the hip joint in up to 15% of individuals [1].

Acquired changes are associated with active disease, whether local or

systemic, including: rheumatoid arthritis, osteoarthritis, infection, tuberculosis, avascular necrosis, synovial chondromatosis, villonodular synovitis, polymyalgia rheumatica, pseudogout, metastatic bone disease, total hip arthroplasty and hip arthrodesis [2,3].

When a communication exists, overproduction of synovial fluid within the hip joint produces a high intra-articular pressure, forcing fluid into the bursa causing progressive enlargement. If no communication exists, fluid production is secondary to inflammation of the synovial lining of the IB itself, producing engorgement. This could result from direct trauma to the bursa [3].

Significant enlargement can cause compression of the femoral nerve with neurological manifestations in its distribution, or the femoral vein impairing venous outflow and producing limb oedema, both of which occurred in our case. Venous thrombosis has been reported, and proved to be fatal in that case [5]. Erosion of the pelvic wall and extension into the pelvis proper is also reported [2,4].

The clinical diagnosis of large iliopsoas bursa can be difficult, but must be considered when assessing a mass in the groin. A thorough history and examination, supported by carefully analysed base-line bloods, is essential. As with our case, a mildly raised D-dimer prompted full anticoagulation therapy for DVT, which is not without risk to the patient.

Ultrasonography (US) is a quick, low-cost and non-invasive first line investigation. In combination with colour Doppler, vascular disorders can be excluded. In our case, ultrasound excluded deep vein thrombosis and prompted further investigation [4].

CT can be used to identify the bursa and its relationship to surrounding structures, however it is poor at demonstrating communications with the hip joint and underestimates the size of the bursa [6].

The gold standard investigation is MRI scanning. It is accurate at depicting size and delineating communication with the hip joint, and also allows evaluation of the hip joint, demonstrating associated avascular necrosis of the femoral head and chronic synovitis [4,6], as well as highlighting malignant conditions. However, it is time consuming and expensive, and some patients may not tolerate the closed environment of the scanner.

Treatment for a massive iliopsoas bursa causing local pressure effects is surgical excision (aspiration carries a high risk of recurrence). Surgery, via an appropriate approach planned from the imaging studies, will allow direct visualisation of the mass and the local structures at risk, as well as ensuring removal in its entirety. Closure of the communication into the hip joint should be performed if present.

Review: Although hip pain is commonly associated with the iliopsoas bursa, a literature search by the authors revealed no previous case reports of neurovascular symptoms caused by an enlarged iliopsoas bursa. As with any medical condition, investigation should begin with a thorough medical history (including drug, past medical and family histories) and clinical examination.

Possible causes of lower limb swelling associated with a mass and neurovascular symptoms can be determined using the 'surgical sieve', and may be due to: trauma, infection, neoplasia, congenital abnormality, vascular insufficiency (venous or arterial), inflammation, bowel hernia or central or peripheral neurological conditions. The majority of these can be ruled out from the history of the progression of the disease, for example, no story of trauma, lack of a fever, timescale of onset and any other systemic or local symptoms.

If, after clinical examination, the diagnosis is still in doubt, then simple, quick investigations should be performed. Basic blood tests would include a full blood count and C-reactive protein in order to provide information on infectious processes. In the context of lower limb swelling, a raised D dimer can be indicative of a DVT. X ray imaging can provide information on bony architecture, but in the case of superficial soft tissues masses, ultrasound would be the radiological imaging of choice, being able to provide information on both vascular involvement (Doppler) and the morphology and content of a mass. All of these tests can be performed in an emergency room setting, and help to differentiate between the majority of diagnoses above, particularly those that pose immediate threat to life or limb (e.g. DVT, arterial ischaemia). Beyond this, MRI and CT imaging can be used to determine more insidious diagnoses that might not otherwise be revealed by other investigations (for example, non-specific inflammatory conditions or soft-tissue or bony neoplasia,

respectively).

Although enlarged iliopsoas bursa is an extremely rare cause of the collection of symptoms described in the case above, this combination of clinical and radiological investigation could have improved the speed of diagnosis and treatment for this patient in two key areas. Firstly, the use of clinical scoring systems, such as the Wells' score in this instance, can be confusing when used out of context: the presence of a groin mass was ignored initially, with the remainder of symptoms correlating with a diagnosis of DVT. Subsequently, risk of bleeding into the mass was then used as a clinical reason for stopping anticoagulant therapy.

Secondly, the patient was discharged without further investigation. Following the US scan, no clear diagnosis or cause for the mass was determined: at this early stage a diagnosis of neoplasia was not considered and the patient was discharged for conservative management of the mass. Fortunately, at follow-up, this was not found to be the case. The decision-making process here highlights two key points in patient care: (1) the value of early patient follow-up (this will reveal whether or not the patient is demonstrating any improvement or worsening, warranting further investigation), and, (2) the importance of reviewing a differential diagnosis when no clear pathology can be found, which in this case would have meant earlier MRI scan and earlier treatment for the appropriate diagnosis.

Conclusion

Massive iliopsoas bursa is a rare cause of swelling in the groin but should be considered in the differential diagnosis. Urgent imaging combining US and MRI will exclude venous occlusion and thrombosis, whilst affording an accurate diagnosis and aid planning of management. Prompt surgical exploration and excision in those with compressive features will result in resolution of symptoms.

References

1. Chandler SB. The Iliopsoas Bursa in Man. *Anat Rec.* 1934; 58: 235-40.
2. Yamamoto T, Marui T, Akisue T, Yoshiya S, Hitora T, Kurosaka M. Dumbbell-Shaped Iliopsoas Bursitis Penetrating The Pelvic Wall: A Rare complication of Hip arthrodesis. *JBJS Br.* 2003; 85(2): 343-345
3. Yoshitaka T, Nishimura I, Mimura T, Ushiyama T, Inoue K, Murakami M. Enlargement of Iliopsoas Bursa in A Patient with Polymyalgia Rheumatica. *J Rheumatol.* 2001; 28(5): 1198-1199.
4. Bianchi S, Martinoli C, Bianchi-Zamorani MP. Giant Iliopsoas Bursitis: Sonographic Findings with Magnetic resonance Correlations. *J Clin Ultrasound.* 2002; 30(2): 437-441
5. McLaughlin GE. Sudden death in rheumatoid arthritis: pulmonary embolism - a fatal complication of Iliopsoas bursitis. *J Clin Rheumatol.* 2002; 8(4):208-11
6. Wunderbaldinger P, Bremer C, Schellenberger E, Cejna M, Turetschek K, Kainberger F. Imaging features of Iliopsoas bursitis. *Eur Radiol.* 2002; 12(2): 409-415.

Conflict of Interest: Nil
Source of Support: None

How to Cite this Article

Jeavons RP, Ryan DJ, Downen D, O'Brien S. Massive Spontaneous Iliopsoas Bursa Mistaken as a Deep Vein Thrombosis. *International Journal of Surgical Cases* 2015 Oct-Dec;1(2): 14-16.