

# Osteochondroma of Great Toe – A Rare Presentation

Vikram V Kadu<sup>1</sup>, K A Saindane<sup>1</sup>, Ninad Goghate<sup>1</sup>, Neha N Godghate<sup>1</sup>

## Abstract

**Introduction:** A subungual osteochondroma is a benign lesion described as a variant of an osteochondroma. It mostly affects the great toe, and it can be confused with an osteochondroma. The curative treatment for a subungual osteochondroma is complete excision, and the cartilaginous cap must be totally resected to prevent a possible recurrence. In this article, we present findings regarding a large and painful lesion on the dorsomedial aspect of the great toe of a patient.

**Case presentation:** 12 yrs old boy presented to OPD with pain over right great toe. Clinically there was redness, swelling, raised local temperature and tender to touch. The patient was investigated in the form of foot x-ray AP and Lateral view. X-ray showed bony overgrowth over the distal phalanx of the great toe. Excision biopsy was done. Patient does not have any complaints.

**Conclusion:** Meticulous history taking regarding the growth of bony lesion is essential to differentiate from rapid growing malignant tumors to slow growing benign tumors. Biopsy is the mainstay of the treatment with HPE for confirmation. The treatment is conservative. If painful, it should be resected.

**Keywords:** Osteochondroma, great toe, paediatric.

## Introduction

The lesions consist of a bony mass, often in the form of a stalk, produced by progressive endochondral ossification of a growing cartilaginous cap. In contrast to true neoplasms, their growth usually parallels that of the patient and usually ceases when skeletal maturity is reached. Most lesions are found during the period of rapid skeletal growth. Trauma is often a precipitating factor and subungual osteochondroma may represent cartilaginous metaplasia occurring in response to acute or chronic irritation [1, 2] X-ray shows large

radiolucent cartilaginous cap [3]. There is no cortical disruption or other abnormality of the distal phalanx [1].


## Case Presentation

12 yrs old boy presented to OPD with pain over right great toe. Clinically there was redness, swelling, raised local temperature and tender to touch [Fig 1]. Meticulous history suggested that the patient was having on and off fever episodes. The patient was investigated in the form of foot x-ray AP and Lateral view. X-ray showed bony overgrowth over the distal phalanx of

the great toe [Fig 2]. Once the patient was fit for surgical management, excision was done. Intra-operatively the swelling was found to be of pea sized situated underneath the nail bed [Fig 3]. The bony overgrowth excised [Fig 4] was sent to histopathological examination for confirmation of diagnosis. The HPE report suggested osteochondroma of the distal phalanx of great toe. The great toe was immobilized for 2 weeks by strapping it with 2nd toe and was kept non-weight bearing. At 6 weeks follow up, the wound was completely healed [Fig 5]. At 2 yrs

Access this article online
Website: www.surgicalcasesjournal.com
DOI:

## Author's Photo Gallery




Dr. Vikram V Kadu



Dr. K A Saindane



Dr. Ninad Goghate



Dr. Neha Godghate

<sup>1</sup>ACPM Medical College, Dhule - 424001, Maharashtra India.

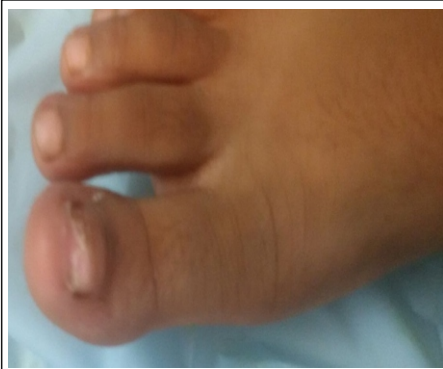## Address of Correspondence

Dr. Vikram Vilasrao Kadu  
C/O vilas shamrao kadu, Plot no. 20, Kadu House,  
Barde layout, Friends colony, Katol Road  
Nagpur - 440013  
Email:- vikram1065@gmail.com

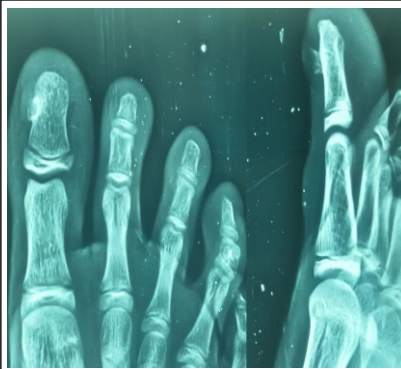
Copyright © 2016 by International Journal of Surgical Cases

International Journal of Surgical Cases | eISSN 2321-3817 | Available on [www.surgicalcasesjournal.com/](http://www.surgicalcasesjournal.com/) |

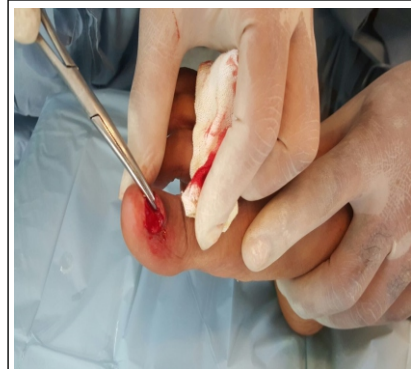This is an Open Access article distributed under the terms of the Creative Commons Attribution Non-Commercial License (<http://creativecommons.org/licenses/by-nc/3.0>) which permits unrestricted non-commercial use, distribution, and reproduction in any medium, provided the original work is properly cited.



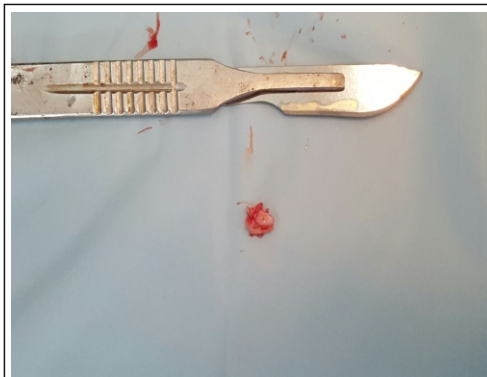**Figure 1.** Clinical picture Pre-op



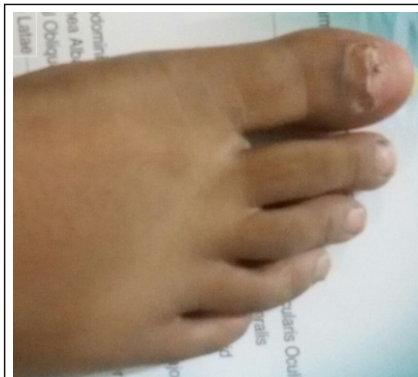**Figure 2.** Pre-op X-ray



**Figure 3.** Intra op clinical picture



**Figure 4.** Excised bony growth



**Figure 5.** Post-op clinical picture

follow-up x-ray was advised which didn't show any bony overgrowth or recurrence.

### Discussion

A subungual osteochondroma is a bony prominence that can occur under the toenail. It is considered a rare variant of osteochondroma [1]. They generally are a result of some form of trauma to the toe that results in the formation of bony irregularity or prominence. When they are symptomatic, removal of the spur is the treatment of choice. Additionally other small tumors called osteochondromas and enchondroma can also form in the bone beneath the toenail as well as in other bones in the body. However, the location and the spindle cell proliferation separate it from an osteochondroma [4]. This lesion is not a true osteochondroma, but an outgrowth of normal bone tissue [5]. It occurs predominantly in children and young adults and often, nearly 80% affects the great toe and rarely other toes [6]. Osteochondromas are small, benign,

bone tumor of the foot [7]. They probably are developmental malformations rather than true neoplasms and are thought to originate within the periosteum as small cartilaginous nodules. Many of these lesions cause no symptoms and are discovered incidentally. Some cause pain by irritating the surrounding structures, and rarely one becomes fractured. False aneurysms of major lower extremity vessels as the result of pressure from osteochondromas have been reported. Also, neuropathies caused by pressure from a contiguous osteochondroma have occurred; the physical finding usually is a palpable mass. Pain, particularly severe on walking, develops due to the collision of the nail plate with the expanding osteochondroma. The overlying nail is pushed up and is finally detached; leading a mass of fibrous tissue whose surface may become eroded and infected. This mass overlies the osteochondroma [8].

The local excision and the removal of the cartilaginous cap is the elective treatment of the subungual osteochondroma.

### Conclusion

Meticulous history taking regarding the growth of bony lesion is essential to differentiate from rapid growing malignant tumors to slow growing benign tumors. Biopsy is the mainstay of the treatment with HPE for confirmation. The treatment is conservative. If painful or associated with complications, it should be resected.

### Clinical Message

Osteochondroma is generally an incidental finding. The treatment is conservative if they are small and without any complication. Surgery in the form of excision biopsy is recommended if associated with pain or complications.

## References

1. ILYAS W., GESKIN L., JOSEPH A. K., SERALY M. P., Subungual osteochondroma of the third toe, *J Am Acad Dermatol*, 2001, 45(6 Suppl):S200–S201.
2. LANDON G. C., JOHNSON K. A., DAHLIN D. C., Subungual exostoses, *J Bone Joint Surg Am*, 1979, 61(2):256–259.
3. CARROLL R. E., CHANCE J. T., INAN Y., Subungual osteochondroma in the hand, *J Hand Surg Br*, 1992, 17(5):569–574.
4. INWARDS CARRIE Y., KRISHNAN UNNI K., Bone tumors. In: STERNBERG S. S. ANTONIOLI D. A., CARTER D., MILLS S. E., OBERMAN H. A. (eds), *Diagnostic Surgical Pathology*, 3rd edition, Volume 1, Lippincott Williams & Wilkins, 1999, 263–315.
5. EVISON G., PRICE C. H. G., Subungual osteochondroma, *Br J Radiol*, 1966, 39(462):451–455.
6. DAVE S., CAROUNANIDY U., THAPPA D. M., JAYANTHI S., Subungual osteochondroma of the thumb, *Dermatol Online J*, 2004, 10(1):15.
7. TUZUNER T., KAVAK A., PARLAK A. H., USTUNDAG N., Subungual osteochondroma: a diagnostic dilemma, *J Am Podiatr Med Assoc*, 2006, 96(2):154–157.
8. AGGARWAL K., GUPTA S., JAIN V. K., MITAL A., GUPTA S., Subungual osteochondroma, *Indian J Dermatol Venereol Leprol*, 2008, 74(2):173–174
9. DUPUYTREN G., On the injuries and diseases of the bones. In: CLARK F. (ed), *Publications of the Sydenham Society*, London, 1847, 408–410
10. DAWBER R. P. R., BARAN R., DE BERKER D., Disorders of nails. In: CHAMPION R. H., BURTON J. L., BURNS D. A., BREATHNACH S. M. (eds), *Rook/Wilkinson/Ebling Textbook of Dermatology*, 6th edition, Volume 4, Blackwell Science, Oxford, 1998, 2815–2869.

**Conflict of Interest: Nil**  
**Source of Support: None**

### How to Cite this Article

Kadu V V, Saindan KA, Goghate N, Godghate N N. Osteochondroma Of Great Toe – A Rare Presentation. *International Journal of Surgical Cases* 2016 Sep - Dec; 2(2): 10-12.